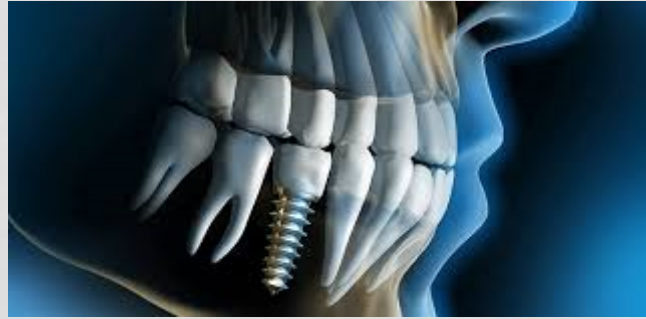


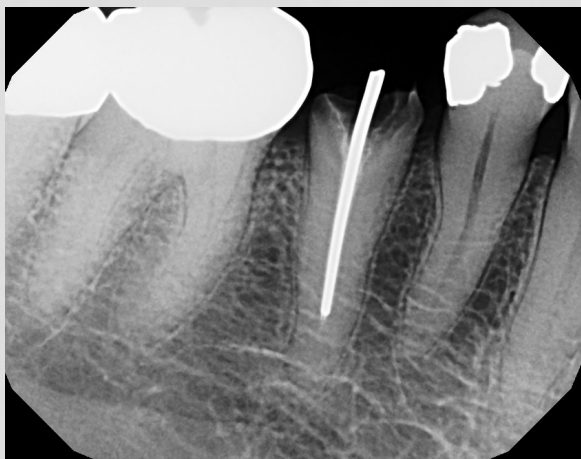


DR. AUSTIN COPE DMD

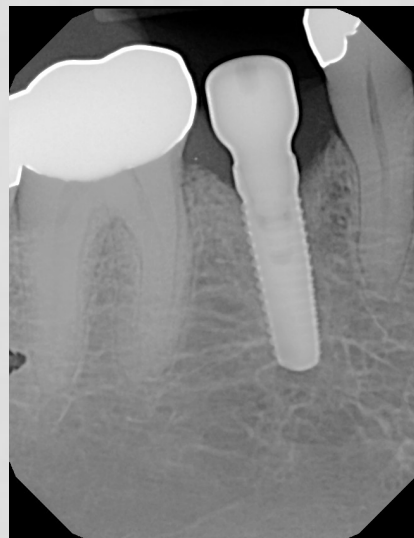IMPLANT CASES



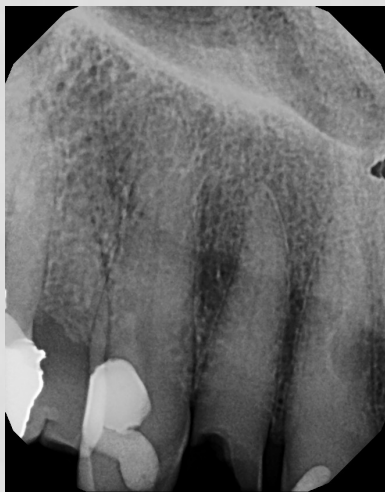• Pre Op



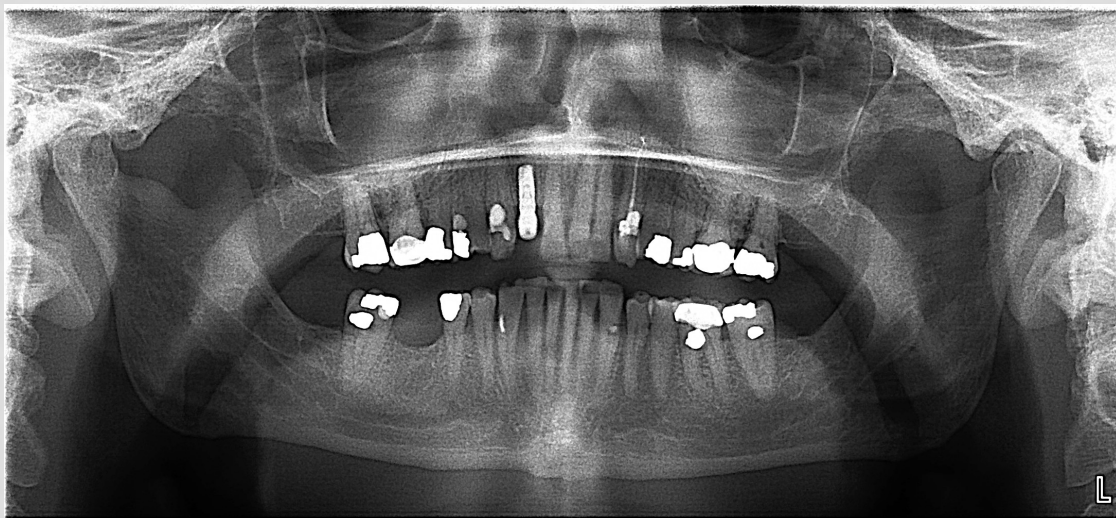
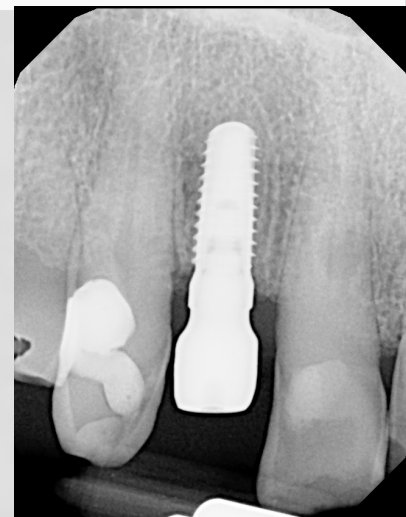1 month post op

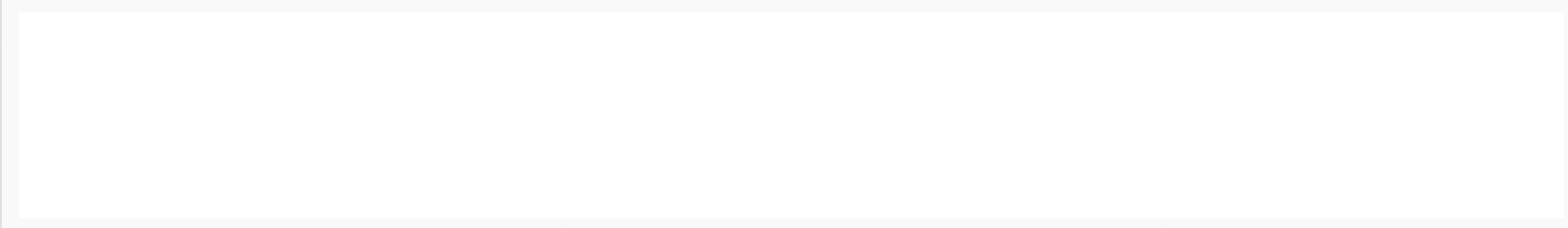


• Pre Op

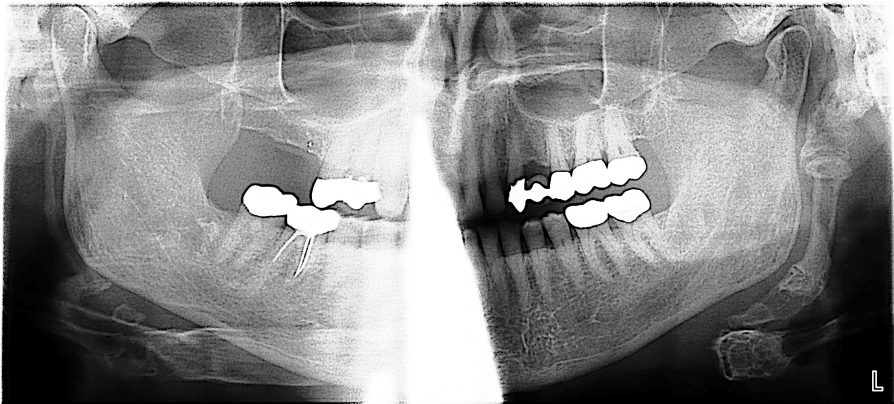


Post op

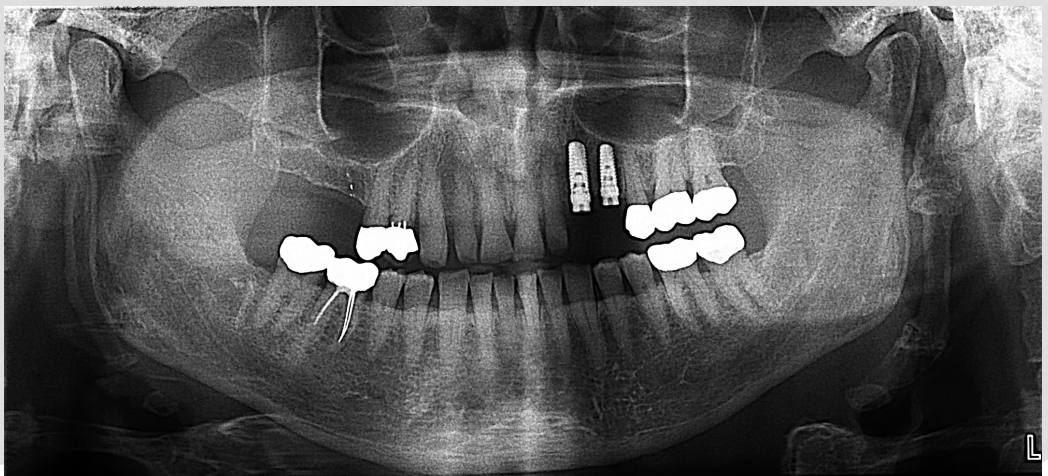
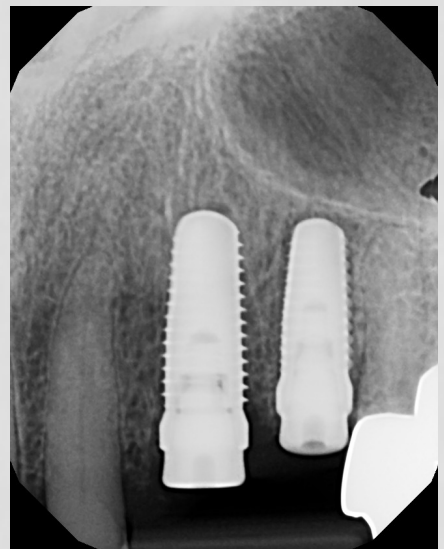



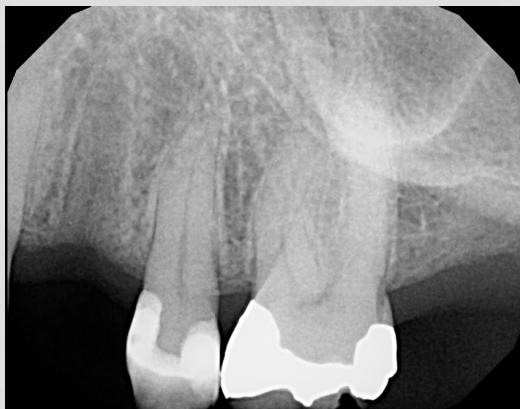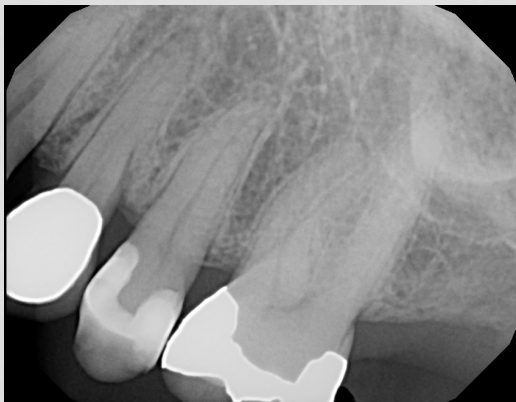• Pre Op



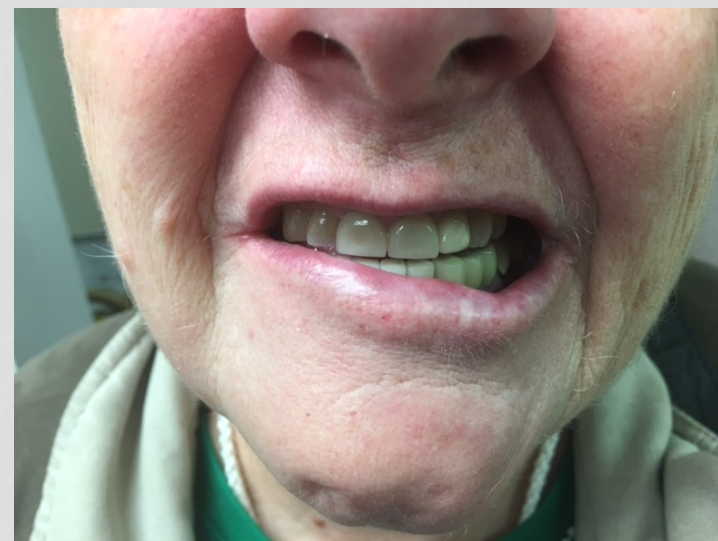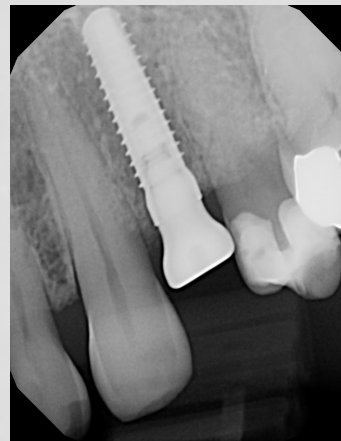
Post op



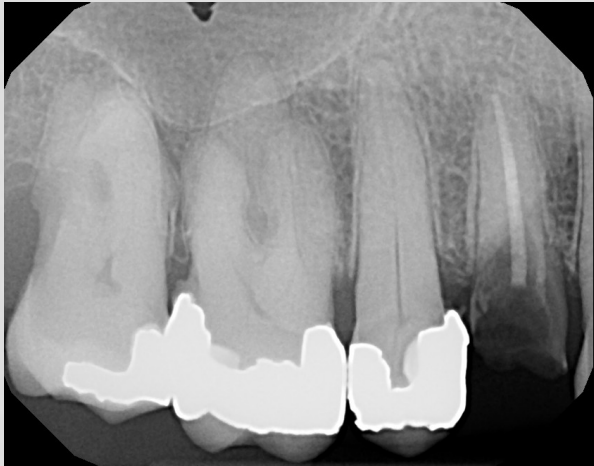• Pre Op



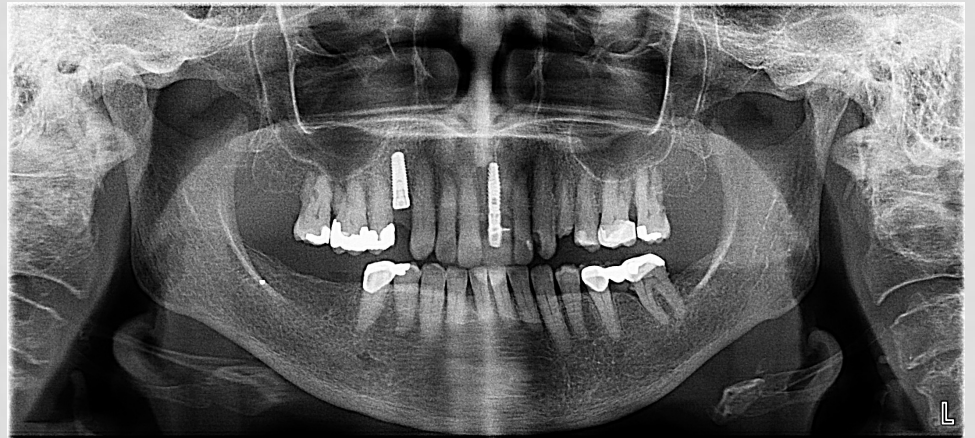
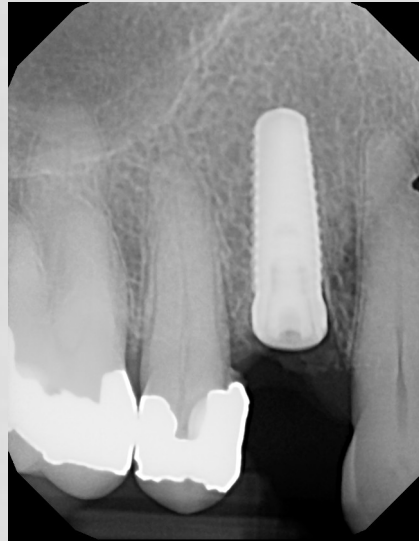Post op

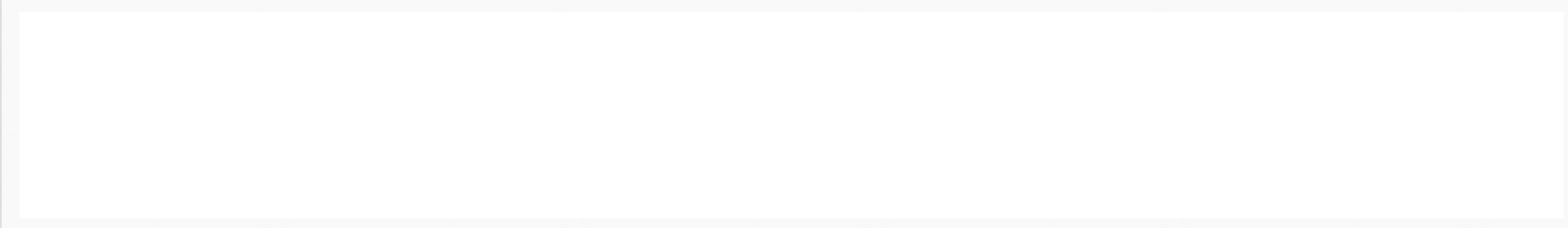


• Pre Op

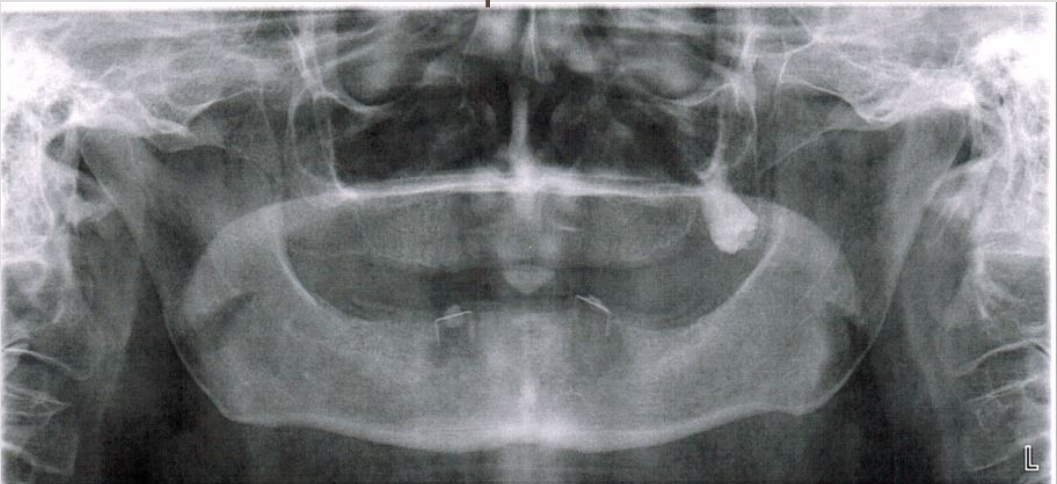


Post op

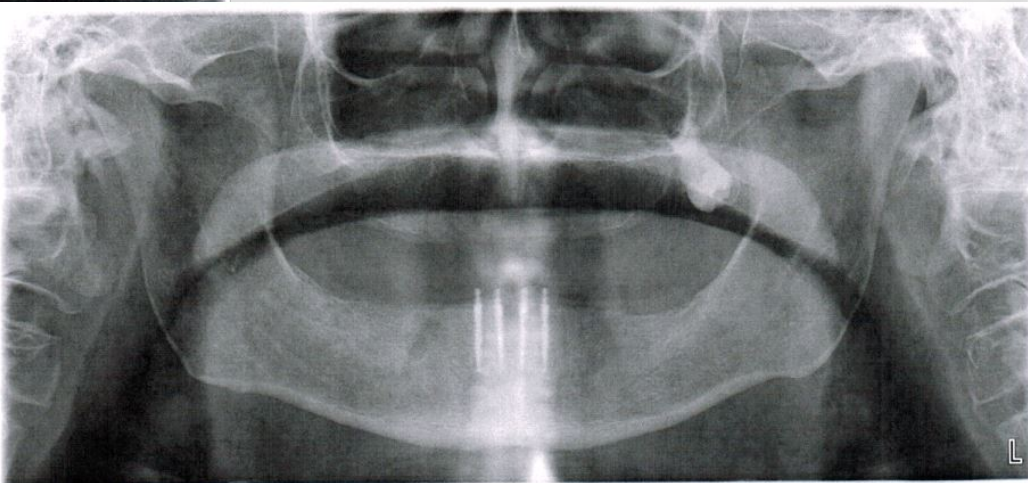




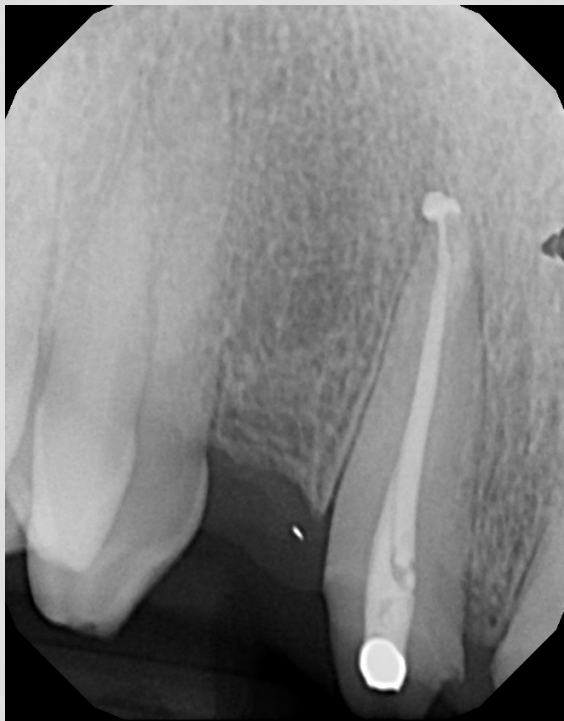• Pre Op



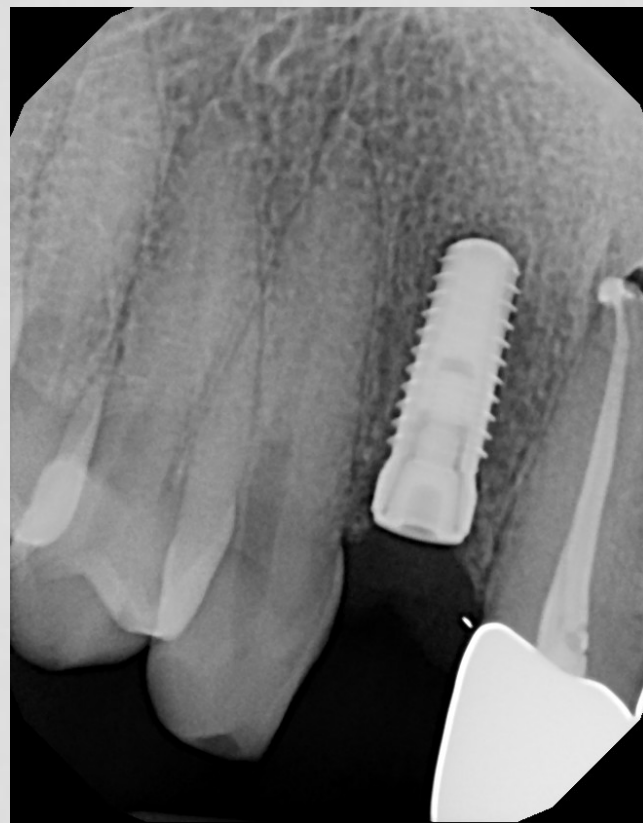Post Op



• Pre Op

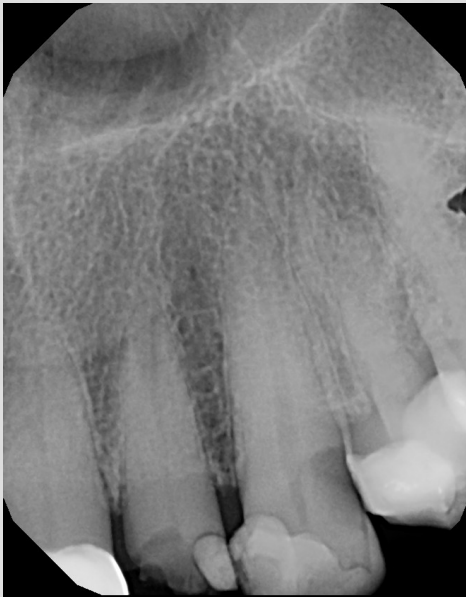

Post Op

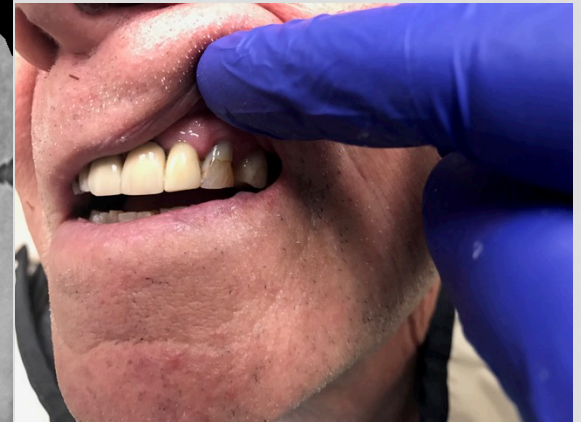
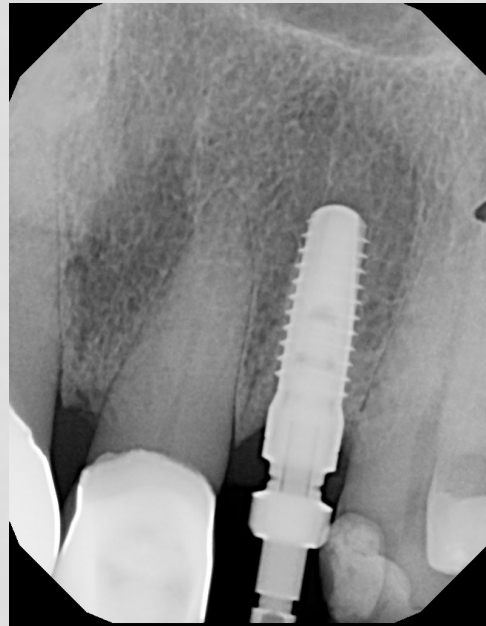



• Pre Op



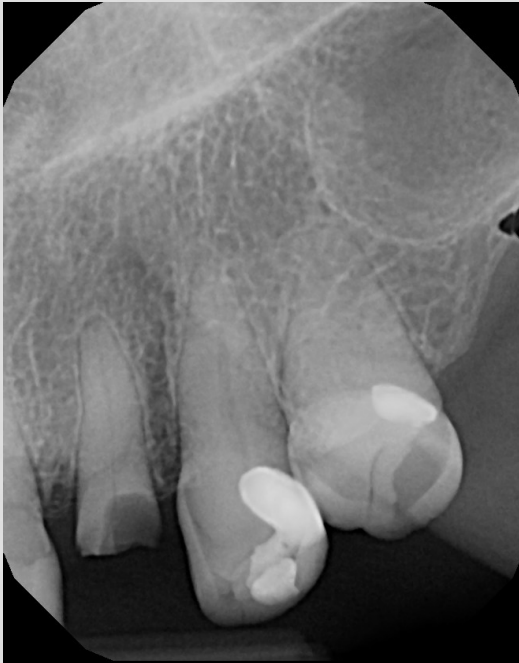Post op



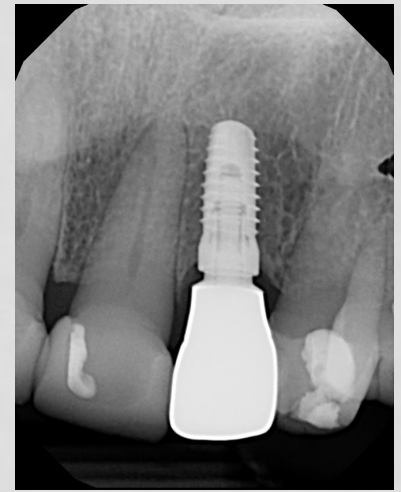
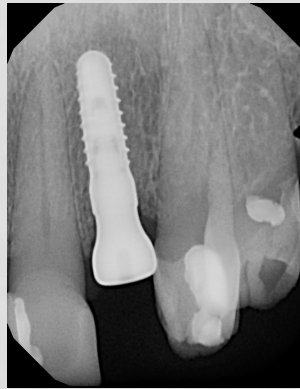

- 

Pre Op



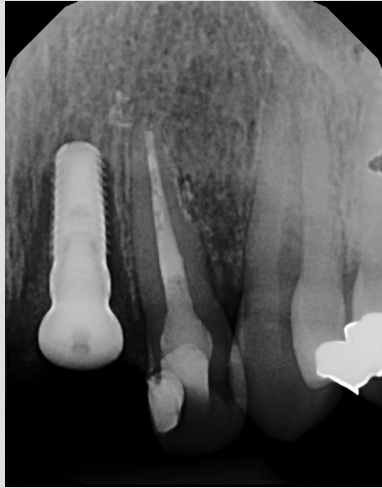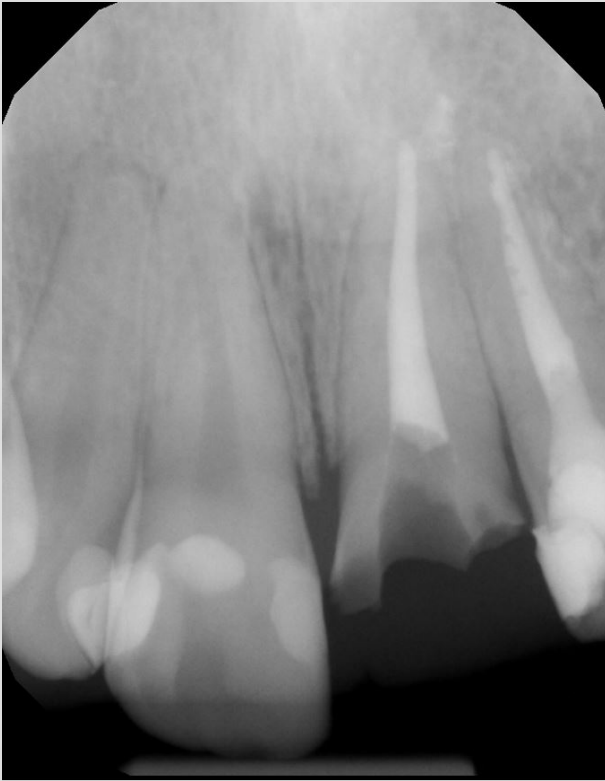
Post Op



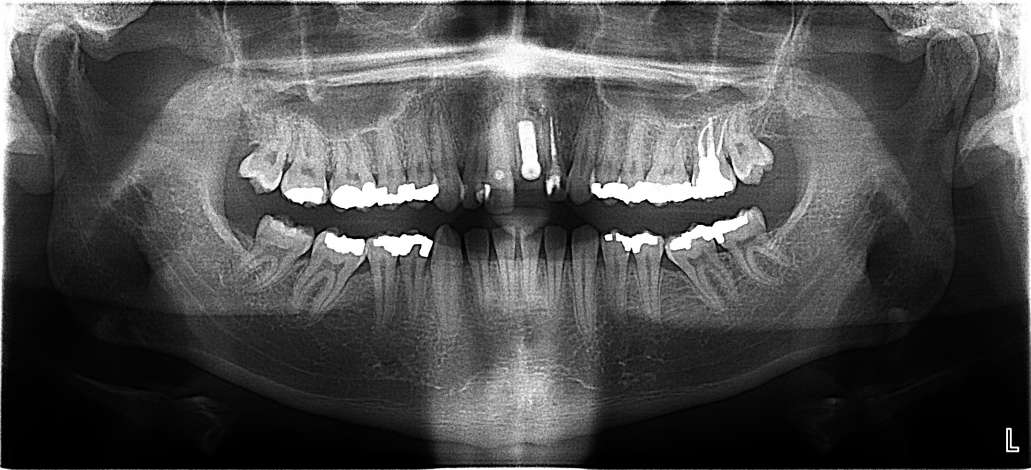
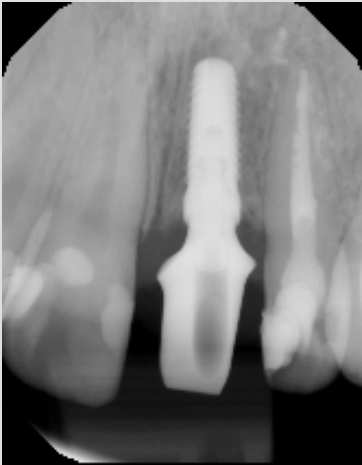
- 

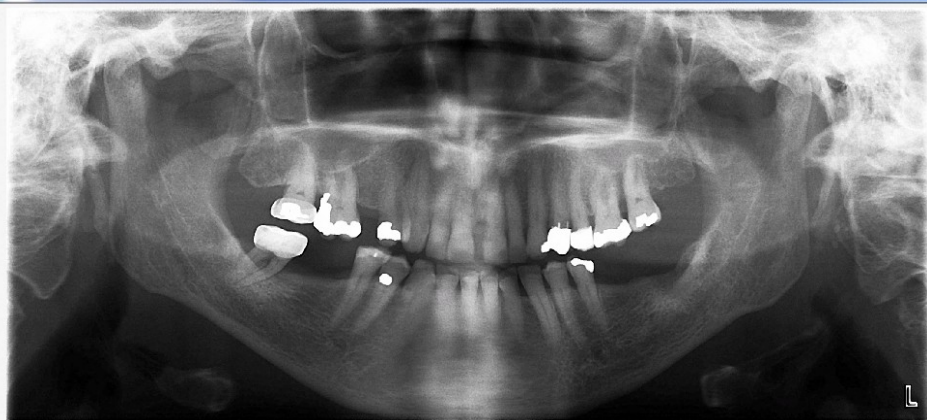
Pre Op



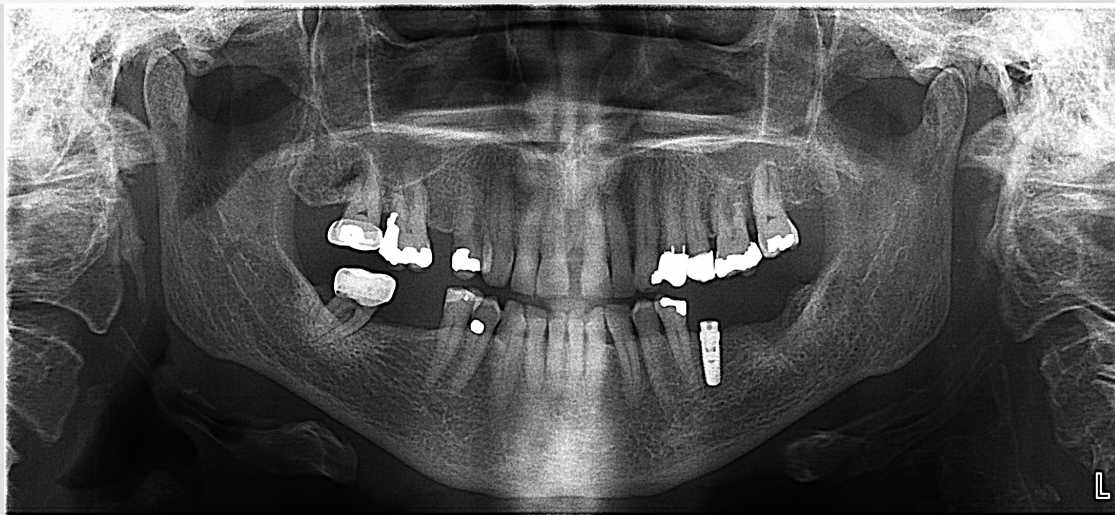
Post Op



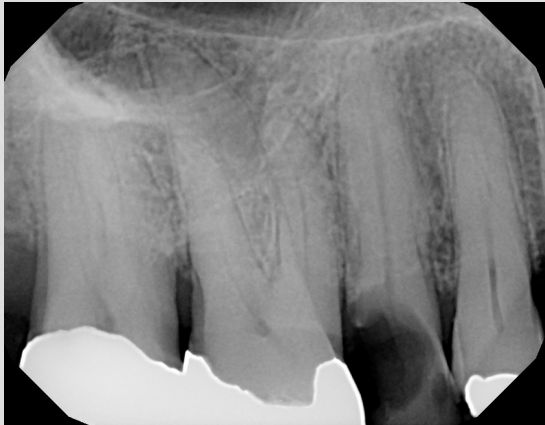• Pre Op



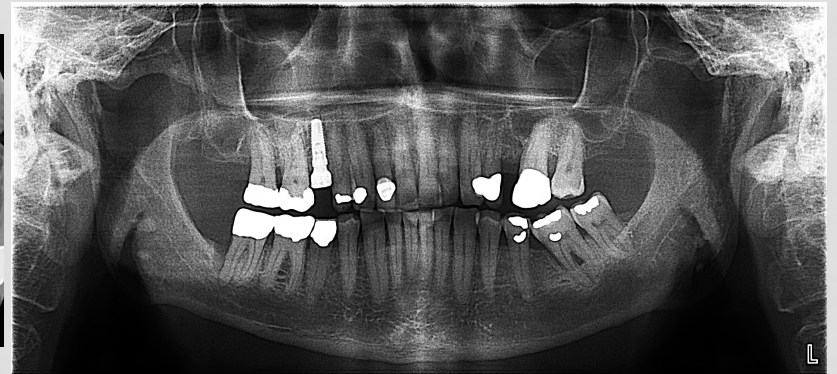
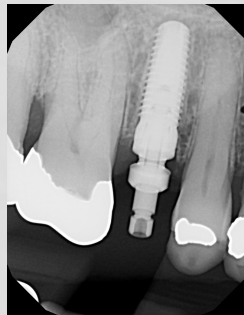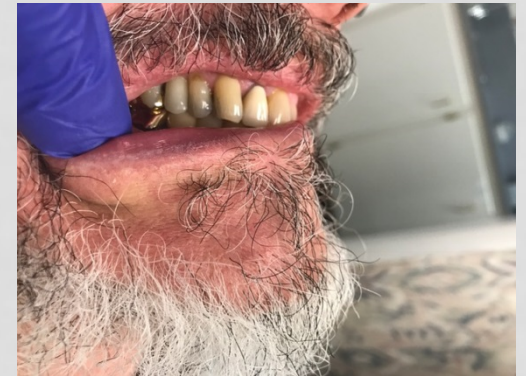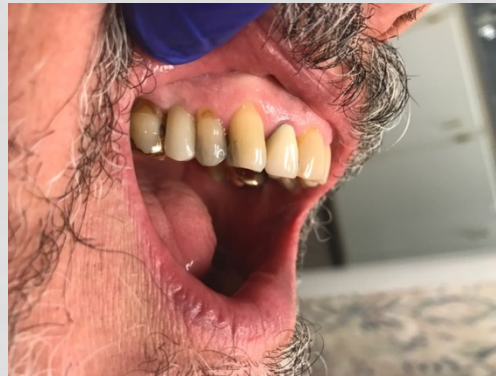Post Op



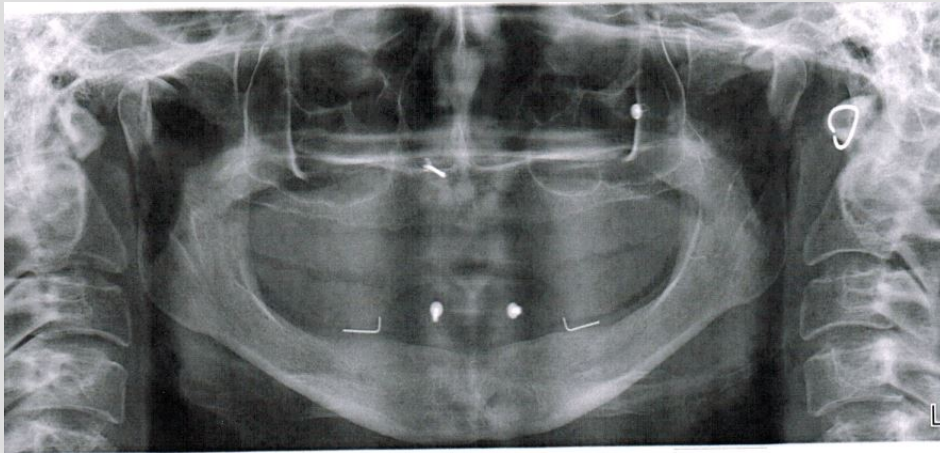
• Pre Op



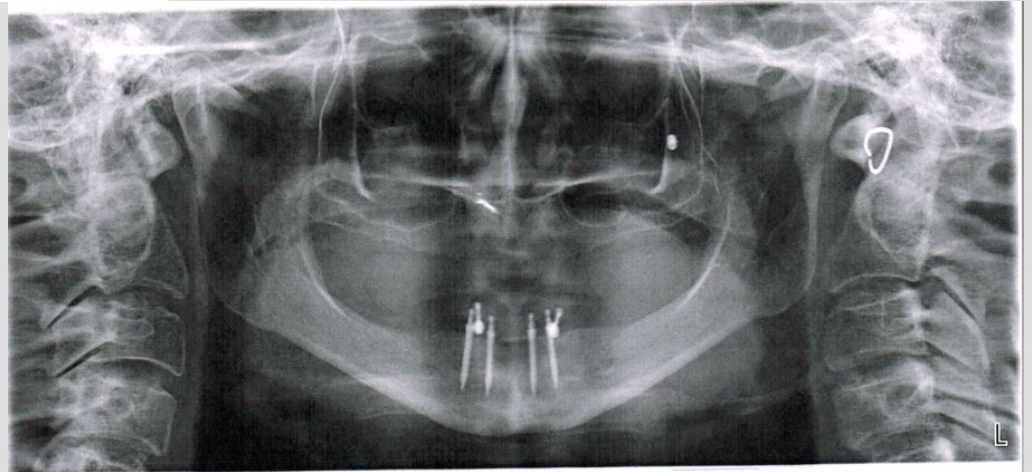
Post Op



• Pre Op

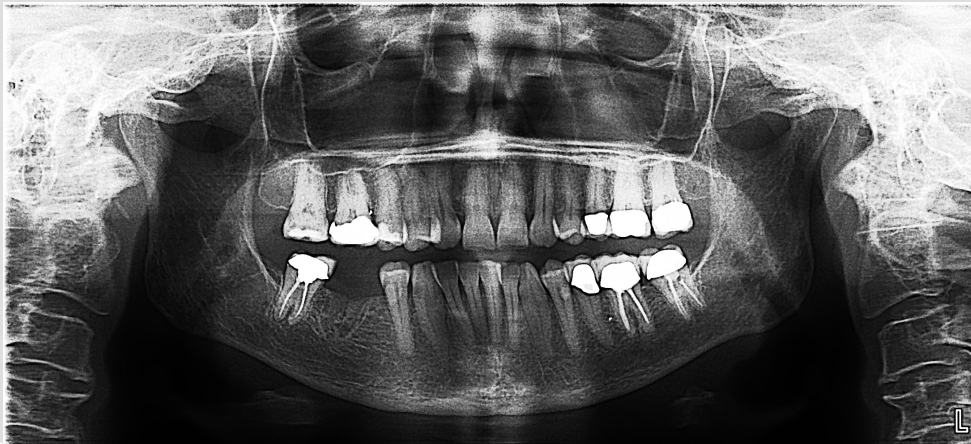
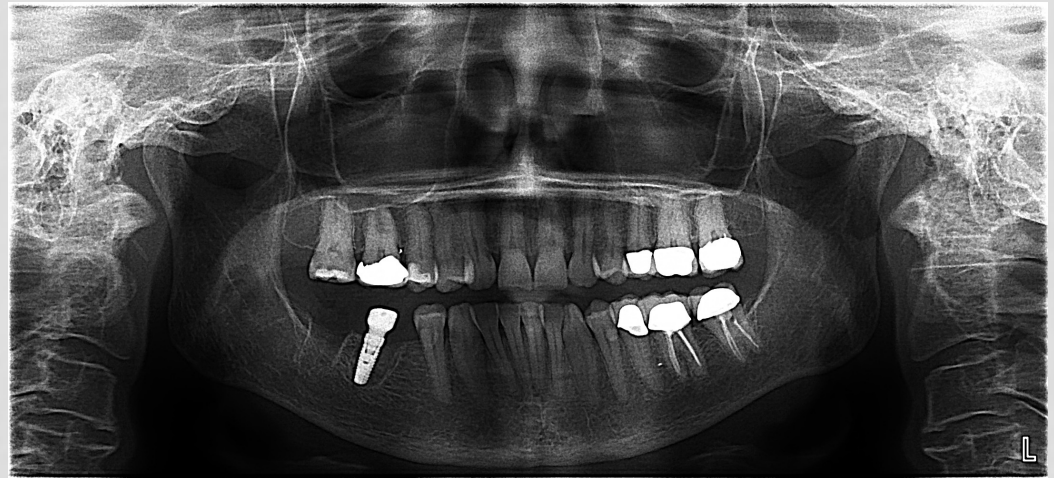

Post Op

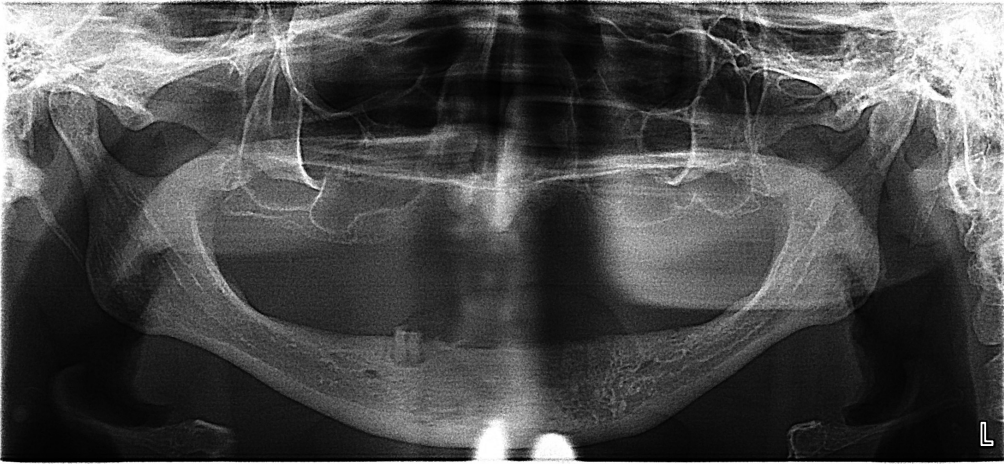


- Pre Op

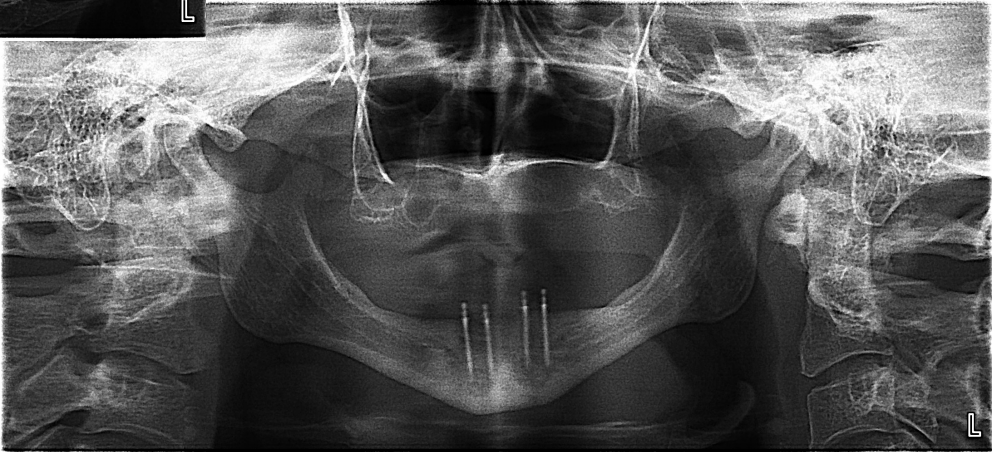
Post Op



• Pre Op

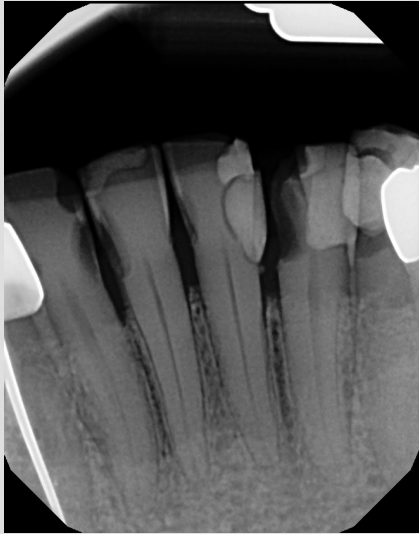

Post Op

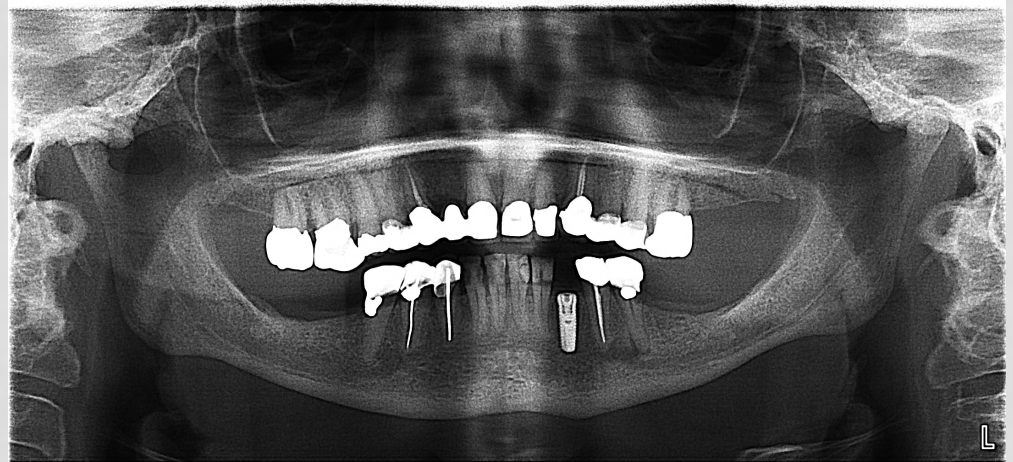
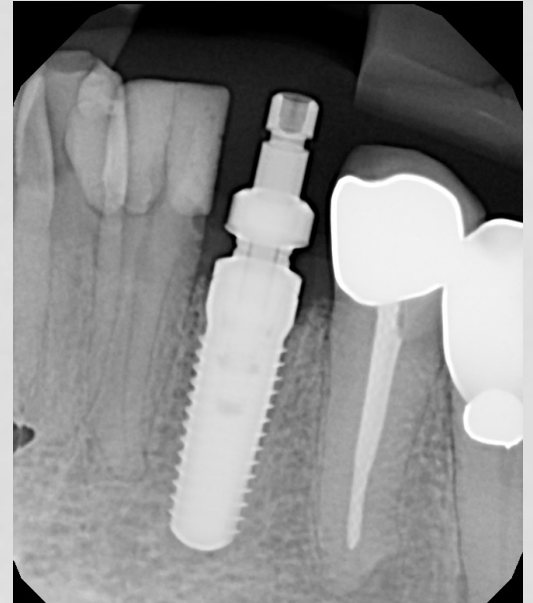




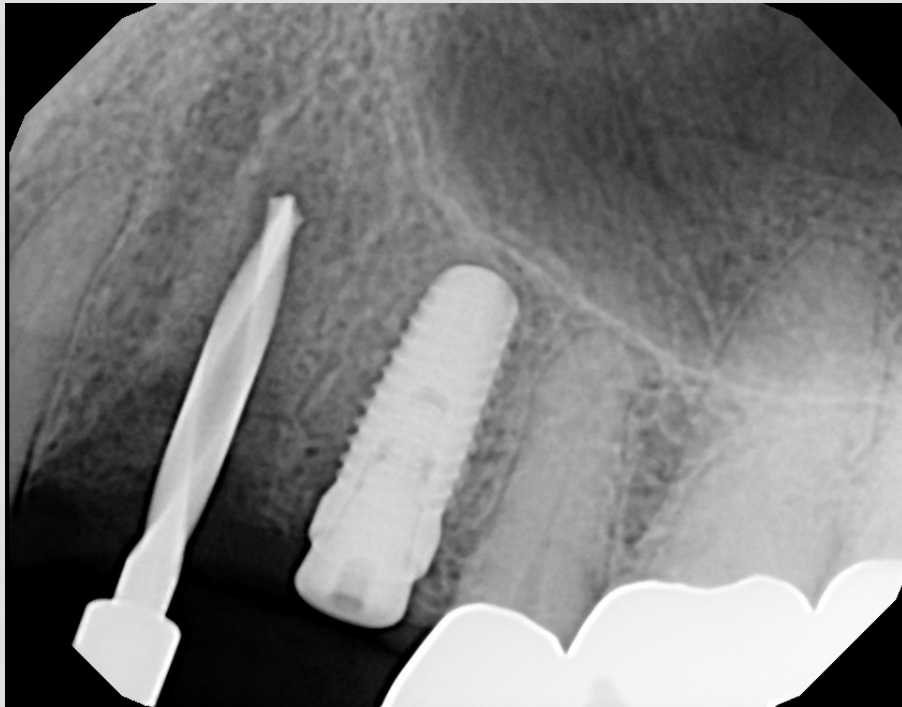- Pre Op



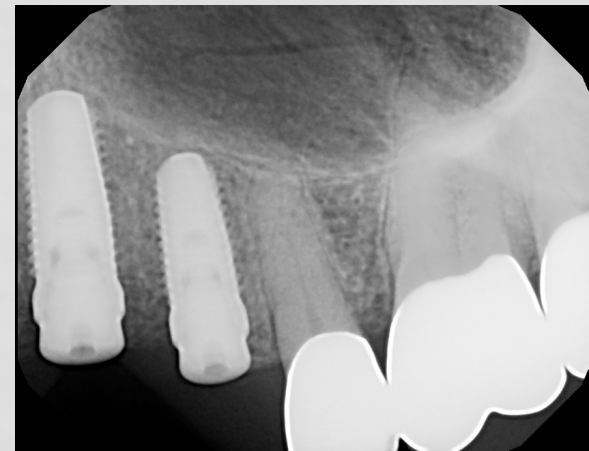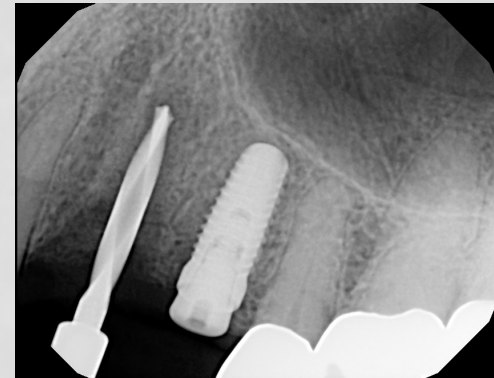Post Op



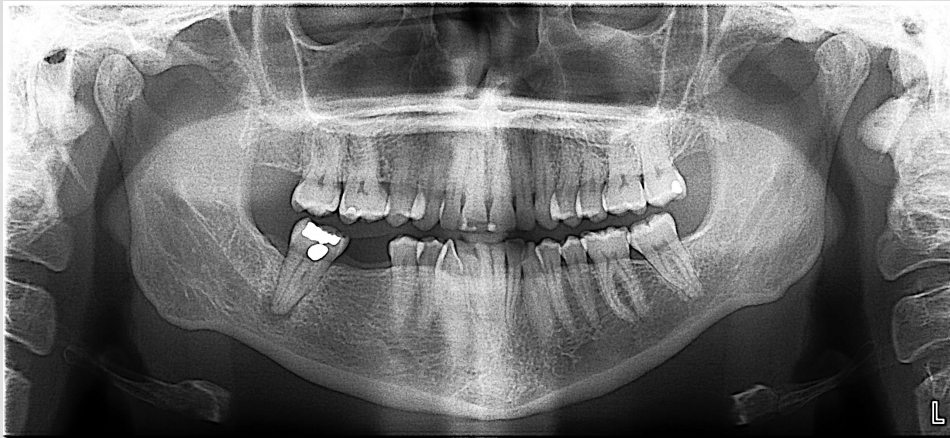
• Pre Op



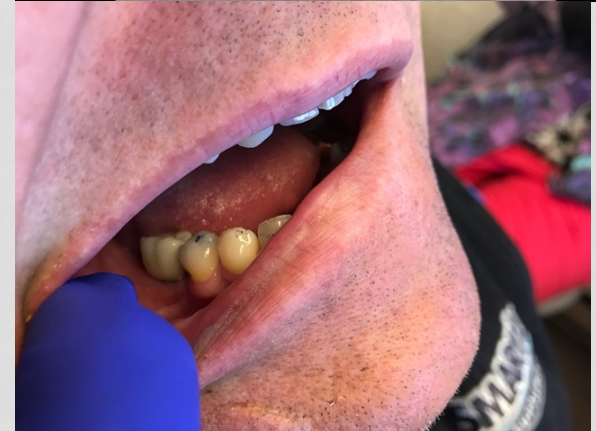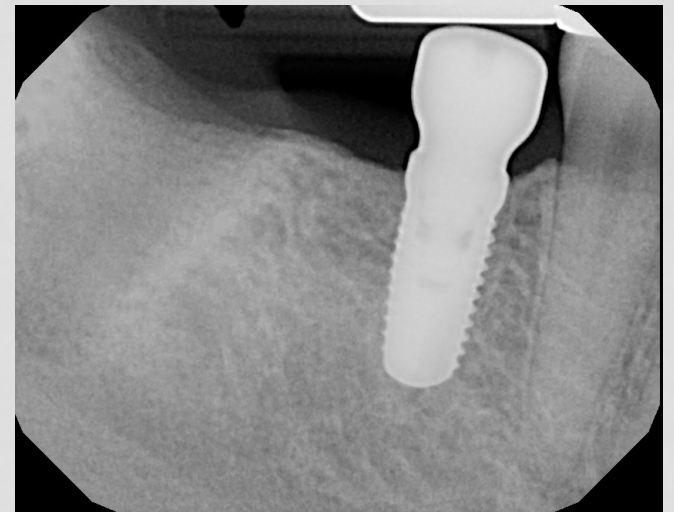
Post Op



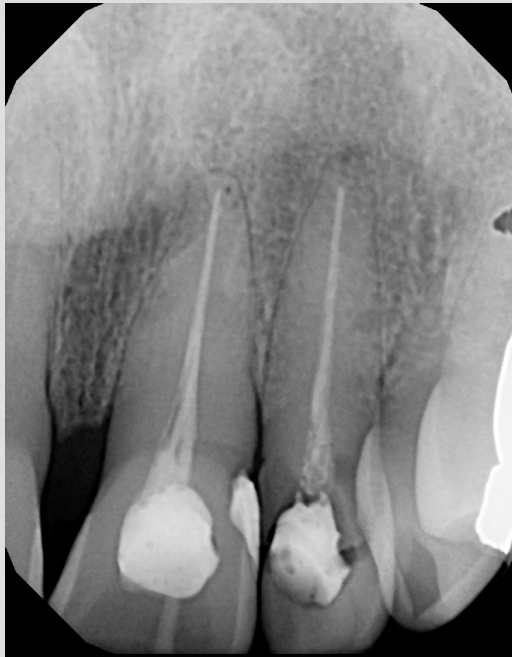- Pre Op



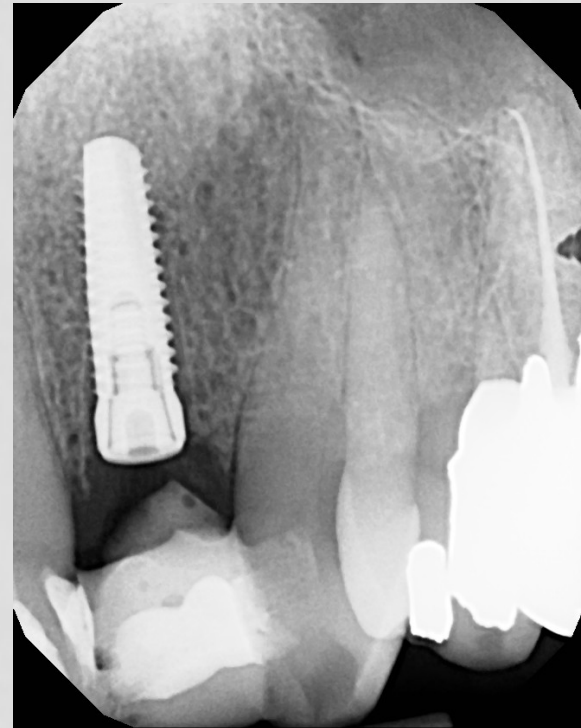
Post Op



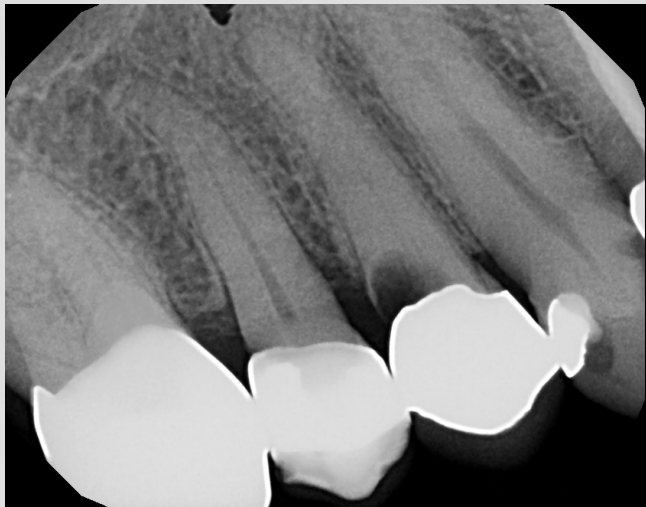
- Pre Op



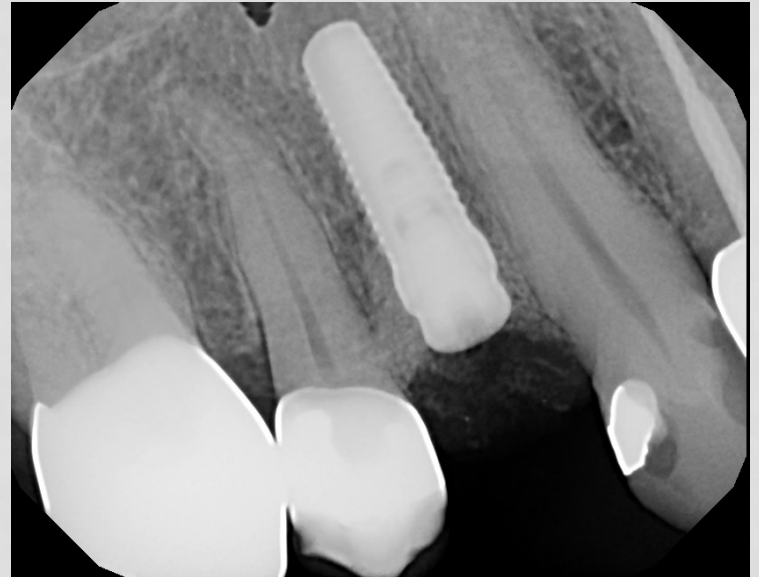
Post Op

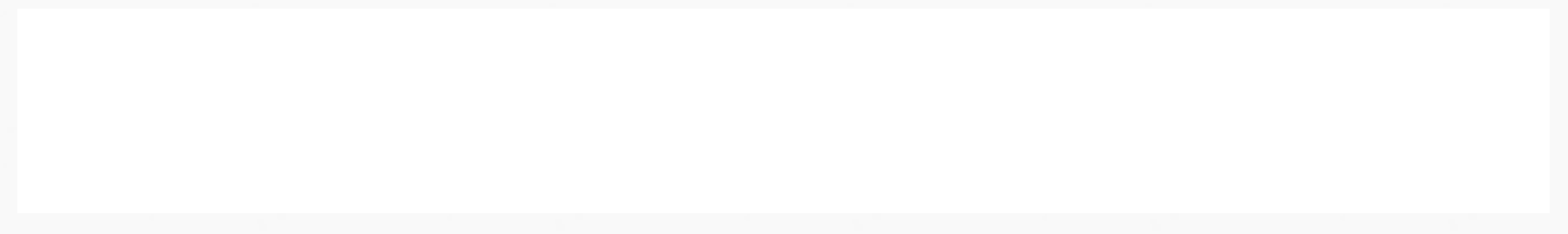


- Pre Op

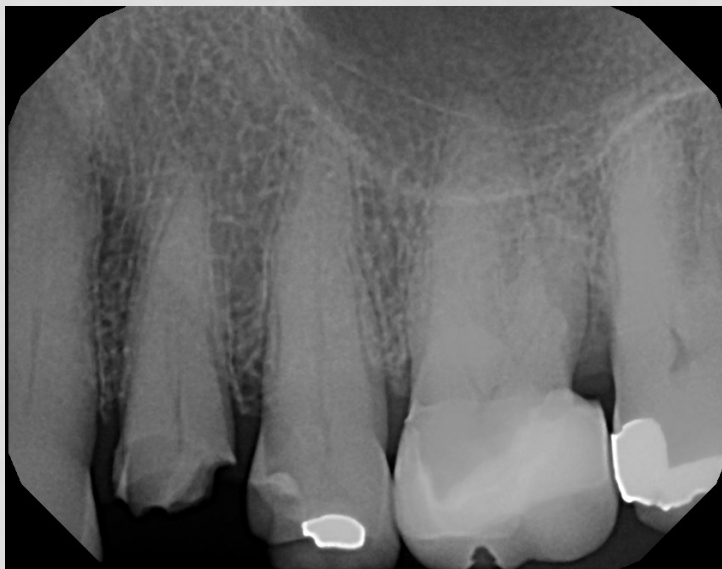

Post Op

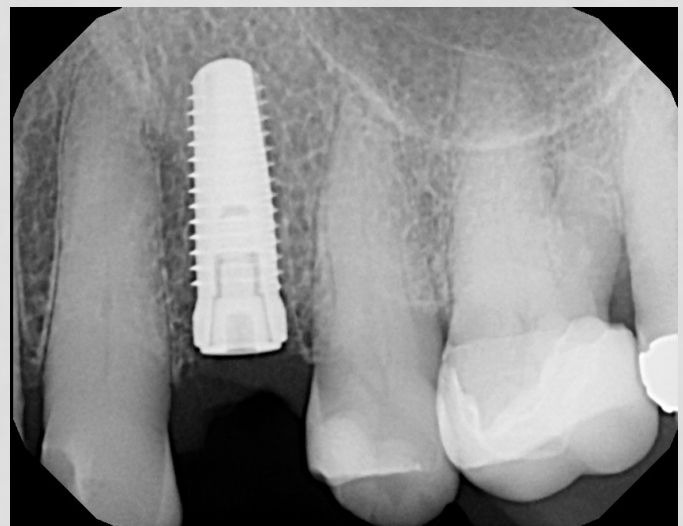




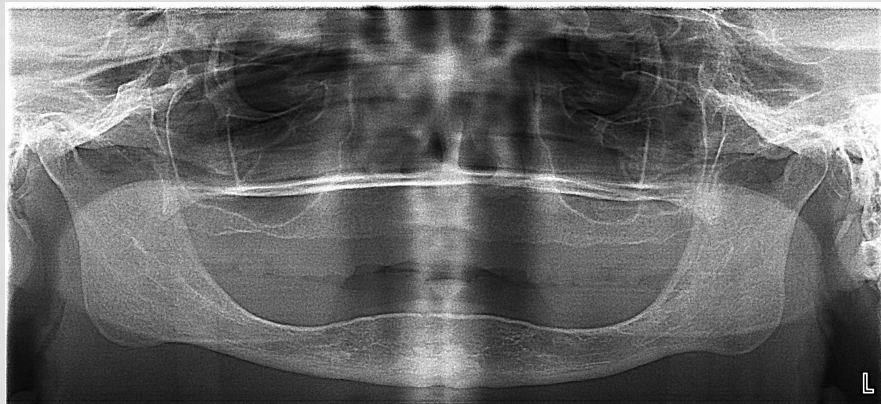
- Pre Op



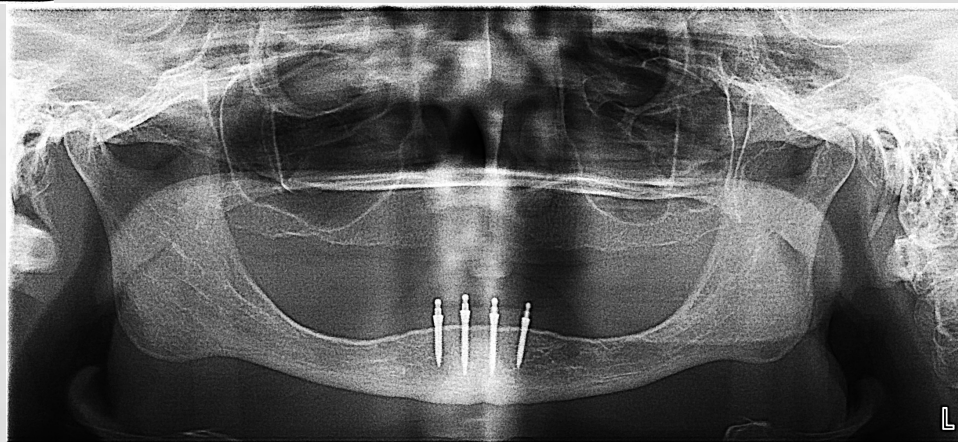
Post Op



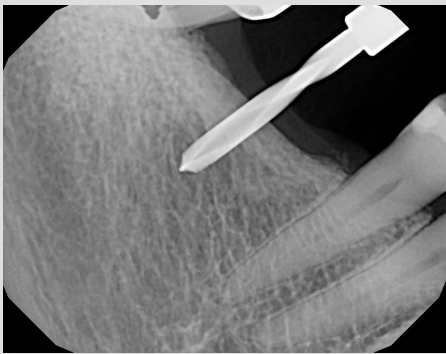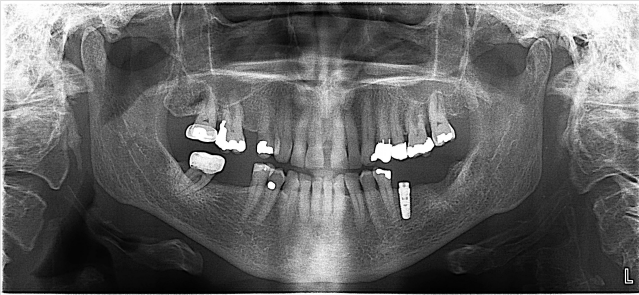
• Pre Op



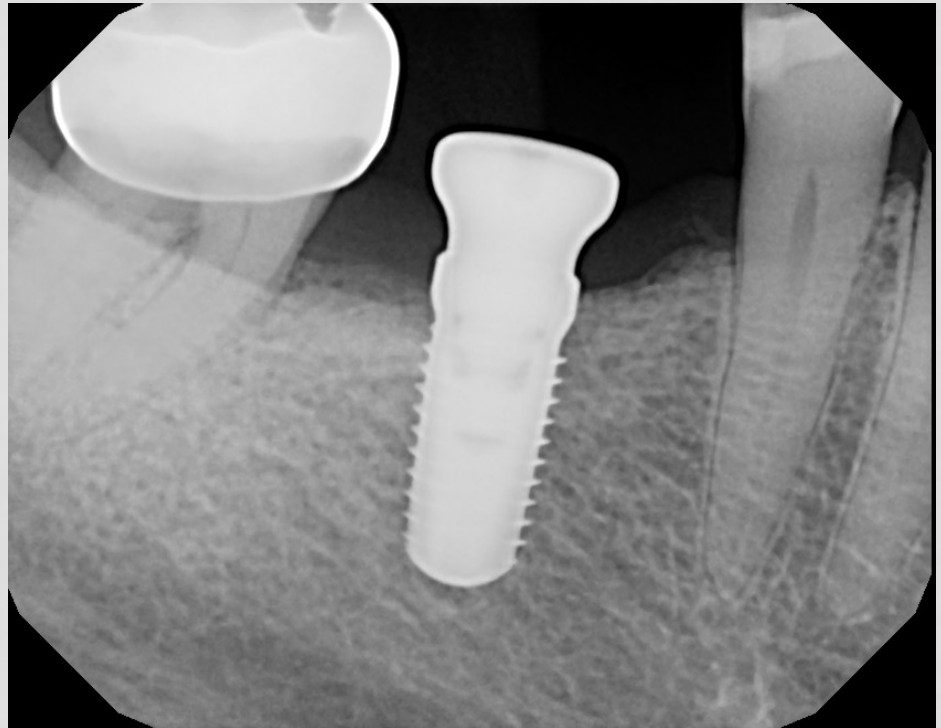
Post Op




- Pre Op



Post Op

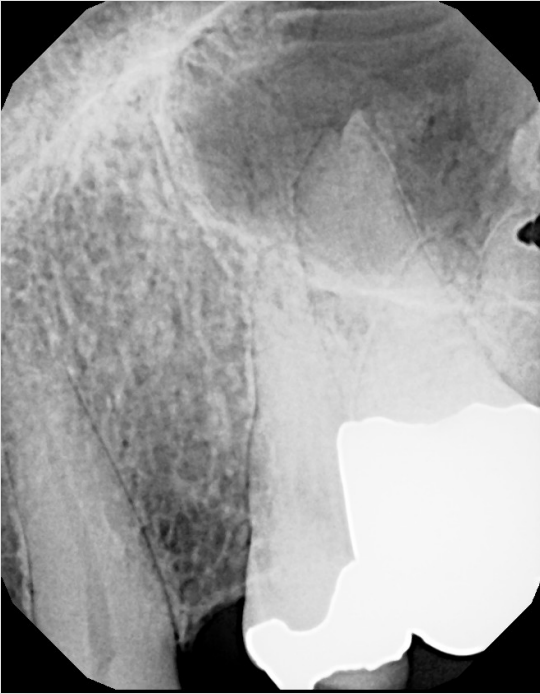




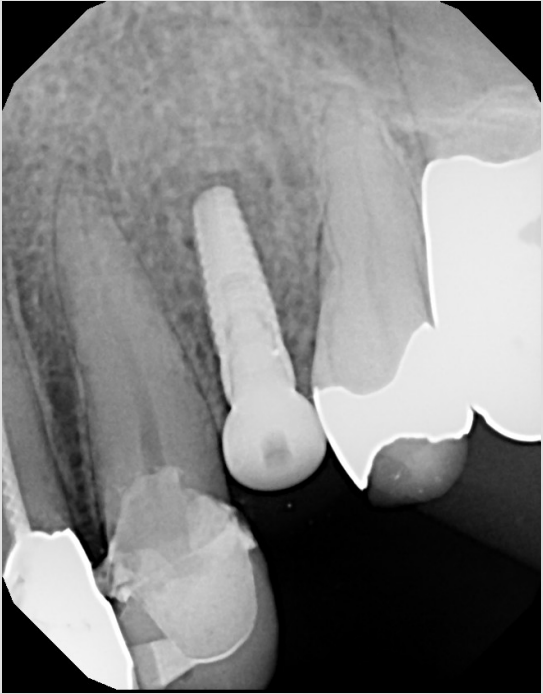

- 

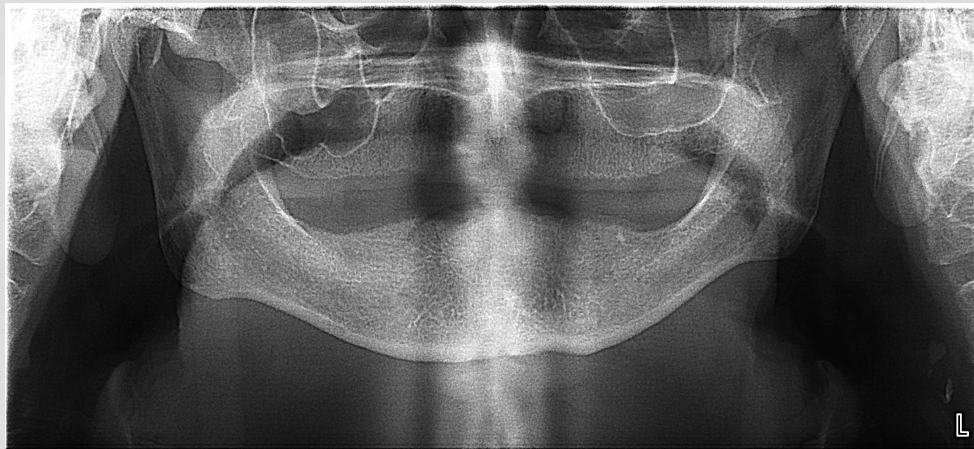
Pre Op



Post Op



• Pre Op



Post Op

